Biochem. Cell. Arch. Vol. 18, No. 1, pp. 605-610, 2018 | www.connectjournals.com/bca | *ISSN 0972-5075*

EFFECT OF DEXAMETHASONE ON THE DISTRIBUTION OF COLLAGEN FIBERS IN THE PREGNANT RAT'S UTERUS : A HISTOLOGICAL STUDY

Alaa Hussein AL-Safy[1] and Akram Yousif Yasear[2]

[1]Department of Biology, College of Education for pure Sciences, Kerbala University, Kerbala, Iraq.
[2]College of Dentistry, Kerbala University, Kerbala, Iraq.

(Accepted 26 February 2018)

ABSTRACT : Dexamethasone as a drug has many clinical usages. It is usually given to the patient before operation to prevent some postoperative complications such as vomiting and nausea. The most widespread use of glucocorticoids is in asthma and inhaled dexamethasone. Dexamethasone is used by patients who are taken chemotherapy for treatment of cancer. Dexamethasone treatment is used by pregnant women for prevention of the respiratory distress in premature delivery. To determine the effect of dexamethasone on distribution of collagen fibers in the pregnant rat uterus during the implantation period on days 7 and 10 dpc (day post coitum). Sixty female rats of confirmed pregnancy have been divided in to two treated groups (48 rats) received intraperitoneally (i/p) 0.2\kg and 0.4 mg \kg dexamethasone respectively and one control group (12 rats) received normal saline via the same route. Histological technique was applied for sections taken from implantation sites at days 7 and 10dpc.the sections were stained in Gomori's one step trichrome stains. Blastocysts were able to implant successfully and have initiated the implantation reaction and decidualization in the uteri of all rats used. As a normal reaction on day 7 dpc collagen fibers was found to be virtually absent in the decidual tissue of primary decidual zone (PDZ) and secondary decidual zone (SDZ)in contrast to undifferentiated zone(UDZ) in which the fibers was widely distributed. On day 10dpc collagen fibers were abundant in the mesometrialdecidual zone (MDZ). Collagen fibers were an important support to the blood vessels in this area which represents a prime route for establishment of nutrient supply through maternal blood vessels supplying the chorioallantoic placenta of rat. The results have revealed that i/p injection of dexamethasone did not interfere with the normal process of implantation of rat blastocyst.

Key words : Dexamethasone, rats, implantation, decidual tissue and collagen fibers.

INTRODUCTION

Collagen is considered as the most widely distributed connective tissue protein in the uterus (Junqueira and Carneiro, 2005). In most species and depending on their reproductive state, adaptive phenotypic changes occur in the uterus, modulated by hormonal variations and mechanical influences that modify its shape (size and weight) and biomechanical properties (distension and growth) (Salinas *et al*, 2016).

Dexamethasone (Dx) is a long acting glucorticoid. It has been used in the treatment of many conditions, including rheumatic problems, a number of skin diseases, severe allergies, asthma, chronic obstructive lung disease, croup, brain swelling, and along with antibiotics in tuberculosis (Ahmadabad *et al*, 2016). Liggins and Howie (1972) were the first to put into clinical practice dexamethasone as a drug of choice to enhance the development of lung to the pregnant mothers who are in a condition of threatened abortion after 26th week of pregnancy. Since that time the use of dexamethasone for such condition became a common practice among the obstetricians.

The question, which has been repeatedly been asked: is the use of Dx for varieties of clinical considerations, during pregnancy, associated with an increasing risk for interfering with implantation and subsequent success of pregnancy and a cause of congenital malformation or not?. Dx is commonly used as steroidal anti-inflammatory drug (Shaikh *et al*, 2012). Many researchers (Michael and Papageorghiou, 2008; Edwards and Burnham, 2001) have stated that Dx used during the first trimester does not represent a major teratogenic risk. Systemic administration of Dx at the time of implantation was associated with retarded fetal development (Gur *et al*, 2004). Normally the process of implantation is marked by development of decidual tissue (Bell, 1983; Finn, 1977). As a consequences to implantation, changes in the distribution of fibrillar components of the extracelullar matrix have been noted in morphological studies of the

rat uterus during pregnancy (Fainstat, 1963; Welsh and Enders, 1991; Clark *et al*, 1992).

Aniline blue staining suggested the absence of collagen bundles throughout the decidual tissue (Fainstat, 1963; Welsh and Enders, 1991; White *et al*, 2004). On day 6-8 of pregnancy, decidual tissue was found to contain very little collagen when compared with non-implantation sites (Martello and Abrahamsohn, 1986). The aim of the present work was to assess the nature of changes in the distribution of collagen fibers in the uterus of the pregnant rat treated with Dx and compare that with normal pregnancy.

MATERIALS AND METHODS

Sixty three month old virgin female rats were used in this experiment. They were maintained under light program of LD 12:12 and fed ad libitum. All experimental rats taken were weighed 175-225 gram. The animals were mated and the day on which spermatozoa were found in the vaginal smear was designated day 1 of pregnancy.

All female rats were divided into two main groups: The G1 group was the rats sacrificed on day 7 of pregnancy (dpc). The G 2 group was the rats sacrificed on day 10 of pregnancy (dpc).

Administration of the drugs

The dexamethasone was available as 2 ml ampoules, each containing 50 mg of the drug.

Calculation of dose

The dose for the rat was calculated according to Pagat and Barnas (1964) equation:

The calculated dose (therapeutic and double therapeutic dose) of dexamethasone drugs were injected intraperitoneally one time daily for six days (G1 group) to the animal sacrificed on the morning of day 7 dpc and for nine days (G2 group) to the animals sacrificed on the morning of day 10 dpc. Normal saline was injected via the same route to the control animals of both groups. Parenteral rather than oral administration was used to ensure that the entire dosage was received by every animal every time.

Tissue sampling and processing

Rats from all subgroups in each critical day were anaesthetized with ether, lapromatized. The uteri were then removed and divided into segments containing the implantation sites. These sites were fixed in 10% formal saline for 48 hours. The samples then dehydrated in ascending grades of alcohol, cleared in xylene and embedded in paraffin wax. The blocks were carefully oriented to have the cross sections to be cut from the implantation sites. Five µm thickness serial sections containing the implantation sites only were cut. The sections were deparaffinied and hydrated for hematoxylin and eosin (for general histological picture). For demonstrating the distribution of collagen fibers Gomoriœ rapid one step trichrome staining (Gomori, 1950) was followed. It stains up collagen fibers green.

RESULTS

Day seven dpc (G1 group)

The findings for hematoxylin and eosin stained sections taken from the implantation sites of control and treated rats at this day of pregnancy were showing the same results regarding the arrangement of decidual tissue. Similarly, the Gomoriœ one step trichrome stained sections have revealed no significant differences in the distribution of collagen fibers.

The initial site of endometrial stromal cells modification for decidualization which has been considered as an indication of successful implantation was in the antimesometrial side of endometrium. Subsequently decidualization has shifted mesometrially. In the sections stained with haemotoxylin and eosin three main zones could be identified (Fig. 1):

1. The primary decidual (PDZ): of closely packed decidual cells that surround the blastocyst and luminal epithelium.
2. The secondary decidual zone (SDZ) situated between PDZ and Undifferentiated basal zone (UBZ) and occupying most of the area of endometrium forming a circle around the PDZ.
3. UBZ: It was a narrow band of tissue extended about ¾ of the way around the circumference of the endometrium separating the decidual of SDZ from the inner circular layer of the myometrium.

G1 (7) = Groups of female rats that were scarified on day (7) dpc2 (10) = Groups of female rats that were scarified on day (10) dpcn= Number of rats in each subgroup. Co = Control rats injected with normal saline.The first subgroup female rats were treated with o.2mg\kg dose of the dexamethasone. The second subgroup female rats were treated with 0.4mg\kg dose of dexamethasone.

The Gomoriœ rapid one trichrome stain had revealed the distribution of collagen fibers in the endometrium and the decidual tissue. The embryo was first located in opposition to the antimesometrial luminal epithelium. This area correlates with the region in which decidualization has been initiated, then progressed mesometrially.

In the PDZ the extracelullar matrix was devoid of collagen fibers, mesometrially and antimesometrially (Fig. 2). The area with minimal amount of collagen fibers corresponds to the differentiating tissue of SDZ. This zone extends around the mesometrial aspect of the uterine lumen and incorporates an area of marked edema (Fig. 3). Dense accumulation of collagen fibers was seen in the stromal tissue of UBZ (Fig. 3) .The collagen fibers of this zone were arranged in a form of whorl around the inactive endometrial glands.

Day 10 dpc (G2 group)

The implantation sites at day 10dpc were exhibiting very clear bead-like appearance in which decidualization was in the highest degree of growth and development.

In hematoxylin and eosin stained sections, the endometrium could be divided into three main zones (Fig. 4):

1. Antimesometrial zone (AMZ): Constitute a zone of tightly packed decidual tissue in the antimesometrial side of endometrium. It was extending toward the nondecidulized tissue the undifferentiated basal zone (UBZ).
2. Undifferentiated basal zone (UBZ): A zone of nondecidulized, undifferentiated stromal cells, located between the myometrium and the fibrinoid capsule.

The cells of this zone resembled the fibroblast- like cells of the original endometrium. They have wide extracelullar space.

3. Mesometrialdecidual zone (MDZ): The MDZ was occupying a triangular area of endometrium located between the myometrium and the mesometrial pole of embryo. The decidual cells of this zone were not densely packed as in ADZ. There was large tortuous blood sinuses associated with this zone radiating from the mesometrial pole of the embryo toward the mesometrial triangle (Fig. 5).

In Gomoriœ one step trichrome stain the collagen fibers were unevenly distributed within the different zones of decidual tissue and the endometrium. The collagen fibers were not displayed in AMZ zone (Fig. 6). But, they were abundantly seen in the mesometrial triangle and the peripheral part of MDZ zone nearest to the myometrium, especially around the blood vessels of this zone (Figs. 5 and 6). High condensation of collagen fibers within the UBZ zone were accumulated in between the undifferentiated stromal cells and the endometrial glands (Fig. 6).

DISCUSSION

One of the prominent results seen in the control and treated animals of this work was the presence of decidual reaction. Welsh and Enders (1991) have pointed out that further expansion and successful development of the conceptus was closely tied to changes in decidua. By comparing the results the results of day 7 and 10 dpc, it was apparent that the endometrium have undergone marked changes reflecting a normal sequence of events seen in normal pregnancy of the rat (Parr *et al*, 1986). It has been shown in the present study that decidualization of endometrial stromal cells is associated with dramatic changes in matrix composition.

Among many features of PDZ demonstrated in the present work was the absence of capillaries, tightly packing of their decidual cells and absence of collagen fibers. In addition to that several kinds of intercellular junctions between cells of this zone have been described viz: tight junctions (Parr *et al*, 1986); gap junctions (Sananes and LeGoascogne, 1976; Lundkvist and Ljungkvist, 1977; Welsh and Enders, 1981; Abrahamson *et al*, 1983; Li *et al*, 2017). These findings suggested a barrier function of PDZ to the trophoblastic invasion during early stages of implantation (Iwahashi *et al*, 1996).

Moreover, the cells of this zone could play a major role in maintaining coherence and structural support to the endometrium during early pregnancy as collagen fibers was absent in this zone.

Present observations regarding the presence of minimal amount of collagen fibers in SDZ was in agreement of Martello and Abrahamsohn (1986). The differing distribution of collagen fibers within PDZ and SDZ may reflect either the degree of decidualization within each area or distinct functional role. The cells of UBZ were not included in the process of decidualization (Parr *et al*, 1986). Thus, by day 7 dpc the UBZ is a wide band of loosely packed tissue. Subsequent growth of the decidual tissue zone at day 10 dpc leads to compaction of the UBZ with regularly arranged bundles of collagen becoming its major constituent.

The present study had demonstrated that one of the demarcation criteria between the decidualized tissue and nondecidulized tissue was marked by the distribution of collagen fibers. The PDZ was devoid of collagen fibers, while SDZ contained only minimal amount of collagen fibers. On the other hand, the UBZ was rich in collagen fibers.

The removal of collagen fibers from around the embryo at implantation site on day 7 dpc was closely related to the progressive steps of decidualization which

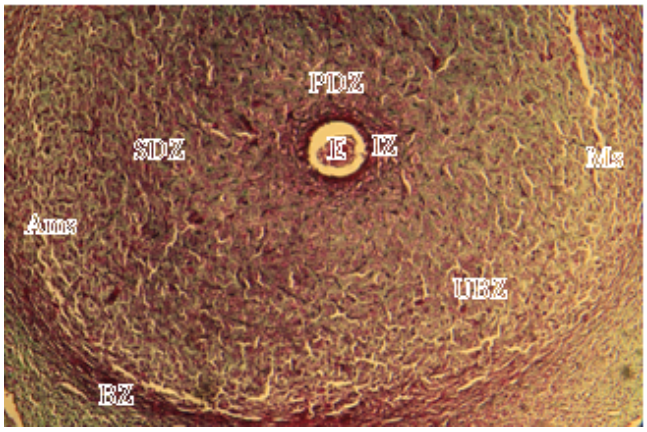

Fig. 1 : Cross section in rat uterus on 7 dpc (Control. Subgroup). Note the presence of decidual reaction. PDZ= Primary decidual zone; SDZ=secondary decidual zone; BZ= basal zone, IZ = implantation zone;UBZ= undifferentiated basal zone; Ms= mesometrial side of endometrium; Am = antimesometrial side. Gomori's one step trichrome stain. 100X.

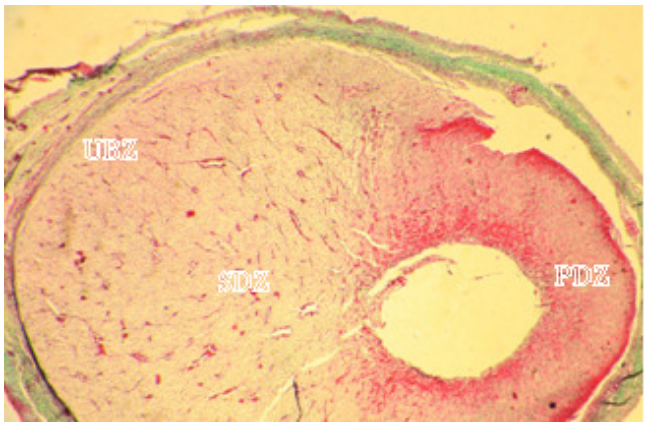

Fig. 2 : Cross section in rat uterus on day 7 dpc of female rat which was treated with therapeutic dose of the Dexamethasone. Note the presence of decidual reaction. PDZ= Primary decidual zone; SDZ=secondary decidual zone; UBZ= undifferentiated basal zone, Note the accumulation of collagen fibers within the UBZ, moderate amount in SDZ, while no collagen fibers within PDZ. Gomori's one step trichrome stain 40X.

Fig. 3 : Cross section in rat uterus on day 7 dpc of female rat which was treated with double therapeutic dose of the Dexamethasone. Note the presence of decidual reaction. PDZ= Primary decidual zone; SDZ=secondary decidual zone; UBZ= undifferentiated basal zone, Note the accumulation of collagen fibers within the UBZ, moderate amount in SDZ, while no collagen fibers within PDZ. Gomori's one step trichrome stain 40X.

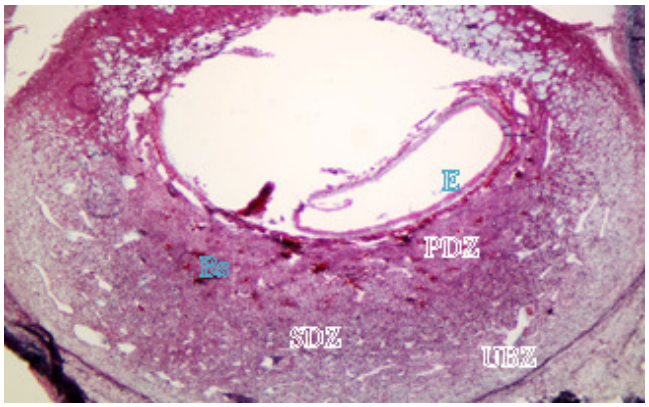

Fig. 4 : Cross section in rat uterus on 10 dpc (Control. Subgroup). Note the presence of decidual reaction. PDZ=Primary decidual zone; SDZ=secondary decidualzone; UBZ=undifferentiated basal zone ; Collagen fibers is only present around theblood sinusoids (Bs) of the mesometrialdecidual zone (MDZ). It is absent from the outer places ofdecidual tissue collagen fiber is only seen at the outskirt (Os) of the DZ adjacent to themyometrium(Mm). Gomori's one step trichrome stain 40X.

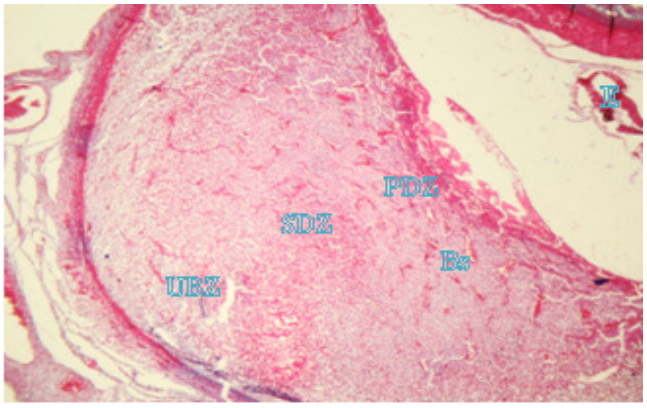

Fig. 5 : Cross section in the implantation site of rat stained for collagen fibers Day10 dpcof female rat which was treated with therapeutic dose of the Dexamethasone. Notice the uneven distribution of the fibers. widely distributed in between decidual tissue and extensivelybranched and tortuous blood sinusoids (Bs) on the mesometrial side (Ms) of endometrium. Theblood sinusoids are continuous with larger blood vessels in the mesometrial triangle (MT) ; E=embryo. Gomori's one step trichrome stain .40 X.

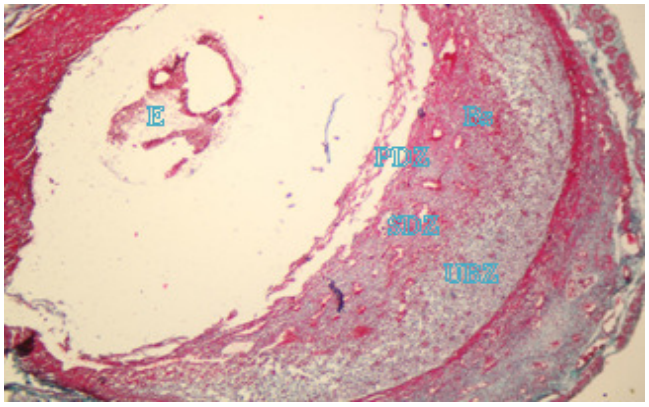

Fig. 6 : Cross section in the implantation site of rat stained for collagen fibers Day 10 dpc of female rat which was treated with double therapeutic dose of the Dexamethasone. Notice the uneven distribution of the fibers. widely distributed in between decidual tissue and extensively branched and tortuous blood sinusoids (Bs) on the mesometrial side (Ms) of endometrium. The blood sinusoids are continuous with larger blood vessels in the mesometrial triangle (MT) ; E= embryo. Gomori's one step trichrome stain .40 X.

was necessary for successful implantation and pregnancy. In the present work, no difference was noted between control and treated rats with regards to the distribution of collagen fibers. Tung *et al* (1986) and Clark *et al* (1993) have reported the absence of collagen fibers from decidual tissue and suggested that cellular adhesion between decidual cells allow to form an immunological barrier protecting the embryo from the mother immune response. If such concept was correct the absence of collagen fibers in decidual tissue during implantation may allow for necessary remodeling needed for establishment of decidual tissue. However, the presence of minimal amount ofcollagen fibers in SDZ may be a stimulus for vasculogenesis. It had been shown that collagen fibers were a stimulating factor for vascular tube formation *in vitro* (Takemori *et al*, 1984). The blood vessels have been noticed to be present in SDZ of the present work and previous studies (Parr *et al*, 1986; Christofferson and Nillson, 1989).

Collagen fibers are likely to be important for support of placental vessels which will be functioning at day 8 dpc in the rat (Clark *et al*, 1993). In this regards sections of day 10 dpc of this study displayed area with abundant amount of collagen fibers in the peripheral parts and around the blood vessels of MDZ nearest to the myometrium and in the mesometrial triangle. These two areas represent the prime route for establishment of nutrient supply via maternal blood vessels to supply the chorioallantoic placenta of the rat (Wooding and Burton, 2008). This correlates with many reports (Welsh and Enders, 1981; Christofferson and Nillson, 1989; Takemori *et al*, 1984) that the mesometrial sinusoids radiating out from the mesometrial aspect of implantations chambers act as a venous system. Fainstat (1963) had explored the disappearance of collagen fibers in the early stage of pregnancy in rat. He concluded that, these fibers broke up into finer filaments during implantation and suggested that local decidual collagenase action released by growing decidua was responsible. It has been shown that the process of degradation of collagenous as well as noncollagenous components of extracelullar matrix is involving a class of enzymes called matrix metalloproteinases (MMPs) (Atkinson and Senior, 2003; Chen and Khalil, 2017). The MMPs enzyme has been localized in the cytotrophoblast cells which migrated to the endometrium during early pregnancy in human (Moll and Lane, 1990) and Macaque (Blankenship *et al*, 1997). The disappearance of collagen fibers from some parts of decidual tissue of the rats in both the control and treated groups raised the question of the involvement of MMPs enzymes released by migrating cytotrophoblast cells in this process. The migration of cytotrophoblast cells has been exhibited in the rat (Pijnenborg *et al*, 1981; Silvaa and Serakides, 2016). MMPs enzymes localization has been noticed to be associated with the migrating cytotrophoblast in this animal (Clark *et al*, 2013).

Our results have revealed that, the intraperitoneally administered dexamethasone, has not interfered with implantation, decidualization and rearrangement of collagen fibers seen on days 7 and 10 dpc,which are essential for successful early pregnancy not just in the rat but in all types of hemochorial placentae (Pijnenborg *et al*, 1981).

The present investigation also raised the question of involvement of other substances, as prostaglandin (Yee and Kennedy, 1991); epidermal growth factor (Irwin *et al*, 1994); insulin like growth factor (Han *et al*, 1996).

However, the use of dexamethasone has been noticed to induce teratogenic effect on the developing fetus in late pregnancy (Cheng *et al*, 2014).

In view of the results of the present work and previous studies, we can advise women in fertile period of life to use dexamethasone with caution especially during ovulation. Further studies are required to elucidate the actual effects of long term use of.

REFERENCES

Abrahamson P O, Lundkvist O and Nilsson O (1983) Ultrastructure of the endometrial blood vessels during implantation of the rat blastocyst. *Cell Tiss Res*. **229**, 269-280.

Ahmadabad H N, Jafari S K, Firizi M N, Abbaspour A R, Fahime Ghafoori Gharib F G, Ghobadi Y and Gholizadeh S (2016) Pregnancy outcomes following the administration of high doses of dexamethasone in early pregnancy. *Clin Exp Reprod Med*. **43**(1), 15–25.

Atkinson J J and Senior R M (2003) Matrix metalloproteinase -9 in lung remodeling. *Am. J.Respir. Mol. Biol.* 28, 12-24.

Bell S C (1983) Decidualization regional differentiation and associated function. *Oxf Rev ReprodBiol*. **5**, 220-271.

Blankenship T N and Enders A C (1997) Trophoblast cell -mediated modifications to uterine spiral arteries during early gestation in the macaque. *Acta Anat*. **158**, 227-236.

Cheng X, Wang G, Lee K K and Yang X (2014) Dexamethasone use during pregnancy: potential adverse effects on embryonic skeletogenesis. *Curr. Pharm. Des.* **20**(34), 5430-5437.

Chen J and Khalil R A (2017) Matrix Metalloproteinases in Normal Pregnancy and Preeclampsia. *Prog Mol Biol. Transl Sci.* **148**, 87-165

Clark D E, Hurst P R, Myers D B and Spears G F (1992) Collagen conceteration in the dissected tissue compartments in the rat uterus on days 6,7 and 8 of pregnancy. *J Reprod Fertil*. **94**, 169-175.

Clark D E, Hurst P E, McLennan I S and Myers D B (1993) Immunolocalization of collagen type I and laminin in the uterus on Days 5 to 8 of embryo implantation in rat. *Anat Rec.* **237**, 8-

20.

Clark P A, Xie J, Li S, Zhang X, Coonrod S and Roberson M S (2013) Matrix metalloproteinase 9 is a distal-less 3 target-gene in placental trophoblast cells. *Am. J. of Physiol*. **305**(2), C173-C181.

Christofferson R H and Nillson B O (1989) Morphology of the endometrial vasculature during early placentation in rat. *Cell Tiss Res*. **253**, 209-220.

Edwards H E and Burnham W M (2001) The impact of corticosteroids on the developing animal. *Pediatr. Res*. **50**, 433–440.

Finn C A (1977) Implantation reaction. In: Wynn R M, editor. *Biology of the uterus* 1st ed. New York Plenum Press. p 245-308.

Fainstat T (1963) Extracellular studies of uterus: I. Disppearnce of of the discrete collagen bundles in endometrial stroma during various reproductive states in the rat. *Am J Anat*. **112**, 337-370.

Gomori G (1950) A rapid one step trichrome stain. *Am. J. Clin. Patho.* **20**, 661-663.

Gur C, Diav-Citrin O, Shechtman S, Arnon J and Ornoy A (2004) Pregnancy outcome after first trimester exposure to corticosteroids : a prospective controlled study. *Reprod. Toxicol.* **18**, 93–101.

Han V K, Basset N, Watton J and Challis J R (1996) The expression of insulin like factor (IGF) and IGF- binding proteins (IGFBP) genes in the human placenta and membranes: evidence for IGF –IGFBP interaction at the fetomaternal interface. *J Clin Endocrinol Metab.* **81**, 2680-2693.

Irwin J C, Dalas Fuentes L and Giudice L C (1994) Growth factor and decidualization *in vitro*. *Ann NY Acad. Sci.* **734**, 7-18.

Iwahashi M, Muragak Y, Ooshima A, Yamoto M and Nakano R (1996) Alterations in distribution and composition of the extracellular matrix during decidualization of the human endometrium. *J. of Reprod. and Ferti*. **108**, 147-155.

Junqueira L C and Carneiro L (2005) *Basic Histology text & atlas*. 11 th edition, The McGraw-Hill companies. P.p. 435-450 .

Lundkvist O and Ljungkvist I (1977) Morphology of the ratendometrial stromaat the appearance of pontamine blue reaction during implantation after experimental delay. *Cell Tiss Res*. **184**, 453-466.

Li S Y, Yan J Q, Song Z, Liu Y F, Song M J, Qin J W, Yang Z M and Liang X H (2017) Molecular characterization of lysyl oxidase-mediated extracellular matrix remodeling during mouse decidualization. *FEBS Lett*. **591**(10), 1394-1407.

Liggins G C and Howie R N (1972) A controlled trial of antepartumglucocorticoid treatment for prevention of the respiratory distresssyndrome in premature infants. *Pediatrics* **50**(4), 515-525.

Martello E M V G and Abrahamsohn P A (1986) Collagen distribution in the mouse endometrium during decidualization. *Acta. Anat*. **127**, 146-150.

Michael A E and Papageorghiou A T (2008) Potential significance of physiological and pharmacological glucocorticoids in early pregnancy. *Hum Reprod Update* **14**, 497–517.

Moll U M and Lane B L (1990) Proteolytic activity of first trimester human placenta: localization of interstitial collagenase in villous and extravilloustrophoblast. *Histochemistry* **94**, 555-560.

Pagat G E and Barnas J H (1964) *Evaluatio of drug activities*. In: Lauroance and Bachanch, Editors, London, Academic press.

Parr M B, Tung H N and Parr E L (1986) The ultrastructure of the primary decidual zone. *Am J Anat.* **176**, 423-436.

Pijnenborg R, Robertson W B, Brosens I and Dixon G (1981) Trophoblast invasion and the establishment of hemochorial placentation in man and laboratory animals. *Placenta* **2**, 71-92.

Salinas P, Maria A, Miglino and Mariano del Sol (2016) Quantification of collagen fibers in canine uteri treated withmedroxyprogesteroneacetate. *Pesq. Vet. Bras.* **36**(12), 1221-1226.

Sananes M and LeGoascogne C (1976) Decidualization in the prepubertal rat uterus. *Differentuiation* 5, 133-144.

Shaikh S, Verma H, Yadav N, Jauhari M and Bullangowda J (2012) Applications of steroid in clinical practice: a review. *Int. Sch. Res. Notices* 1–11.

Silvaa J F and Serakides R (2016) Intrauterine trophoblast migration: A comparative view of humans and rodents. *Cell Adh. Migr*. **10**(1-2), 88–110.

Takemori K, Okamura H, Kanzaki H, Koshida M and Konishi I (1984) Scanning electron microscopic study on corrosion castoff rat uterine vasculature during the first half of pregnancy. *J. Anat.* **138**, 163-73.

Tun H N, Parr M B and Parr E L (1986) The permeability of primary decidual zone in rat uterus: An Ultrastructural study and freez fracture study. *Biol. Reprod.* **35**, 1045-1058.

Welsh A and Enders A C (1991) Chorioallantoic placenta formation in the rat: I Luminal epithelial cell death and the extracelullar modifications in the mesometrial region of implantation chambers. *Am J Anat*. **192**, 215-231.

White C A, Robb L and Salamonsen L (2004) Uterine extracellular matrix components are altered duringdefective decidualization in interleukin-11 receptor α deficient mice. *Reproductive Biology and Endocrinology* **2**, 76-91.

Welsh A O and Enders A C (1981) Development and regression of antimesometrial decidua of the rat uterus during normal pregnancy: a light and electrone microscopic study. *Anat Rec*. **199**, 272 A.

Wooding F B P and Burton G (2008) Comparative Placentation:Structures, Functions and Evolution. 47-81. Springer.

Yee G M and Kennedy T G (1991) The role of cyclic adenosine 3-monophosphate in mediating the effect of PGE2 on decidualization *in vitro*. *Bio. Reprod.* **45**, 163-171.